

ELECTRO CARDIO GRAM

BY DR. DINESH CHOUHAN

INTRODUCTION

ELECTROCARDIOGRAPHY

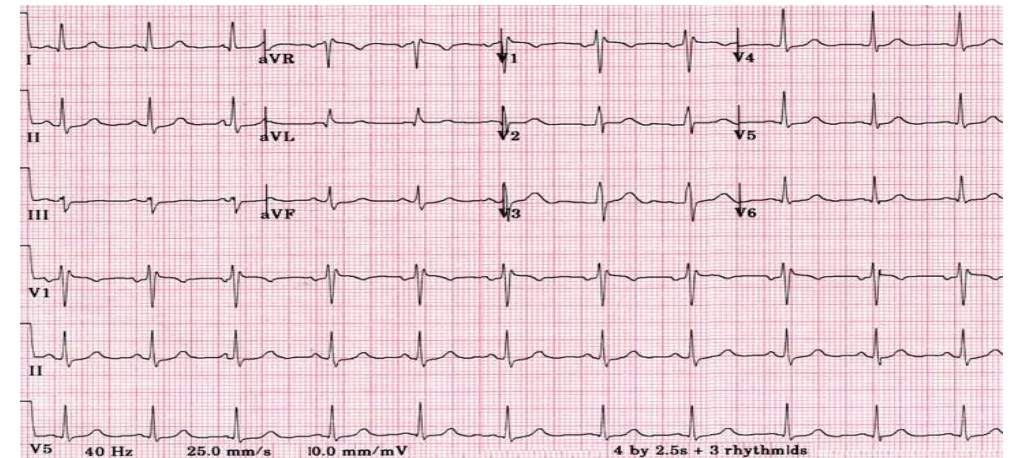
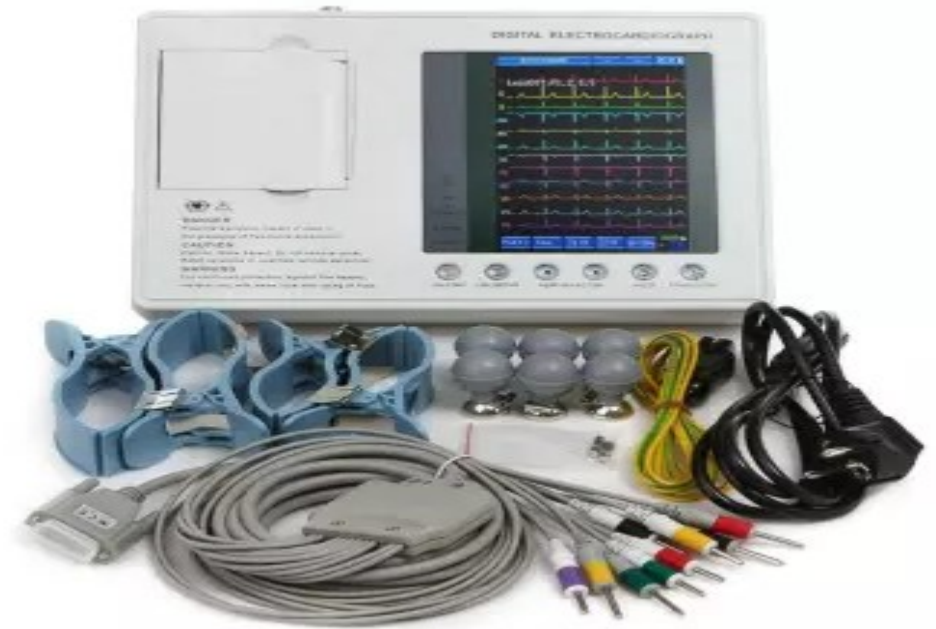- Electrocardiography is the **technique** by which electrical activities of the heart are studied.
- The spread of excitation through myocardium produces local electrical potential.
- This low-intensity current flows through the body.
- This current can be picked up from surface of the body by using suitable electrodes and recorded in the form of electrocardiogram.
- This technique was discovered by Dutch physiologist, **Einthoven Willem**, who is considered the father of electrocardiogram (ECG).

ELECTROCARDIOGRAPH

- Electrocardiograph is the **instrument** (machine) by which electrical activities of the heart are recorded.

ELECTROCARDIOGRAM

- Electrocardiogram (ECG or EKG from elektrokardiogram in Dutch) is the record or **graphical registration** of electrical activities of the heart, which occur prior to the onset of mechanical activities.
- It is the **summed electrical activity** of all cardiac muscle fibers recorded from surface of the body.



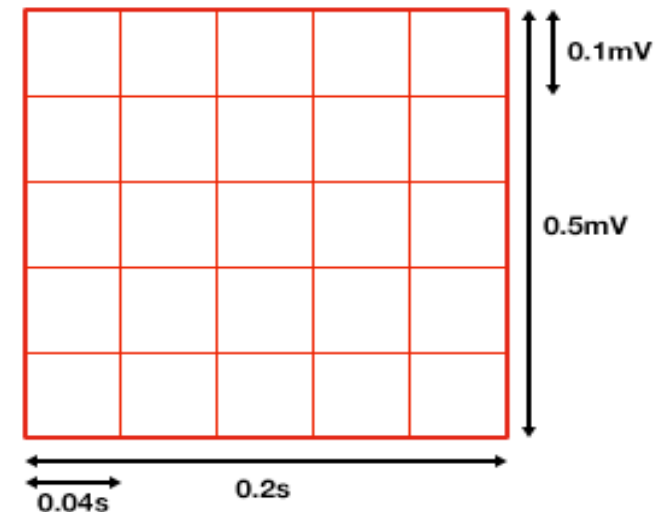
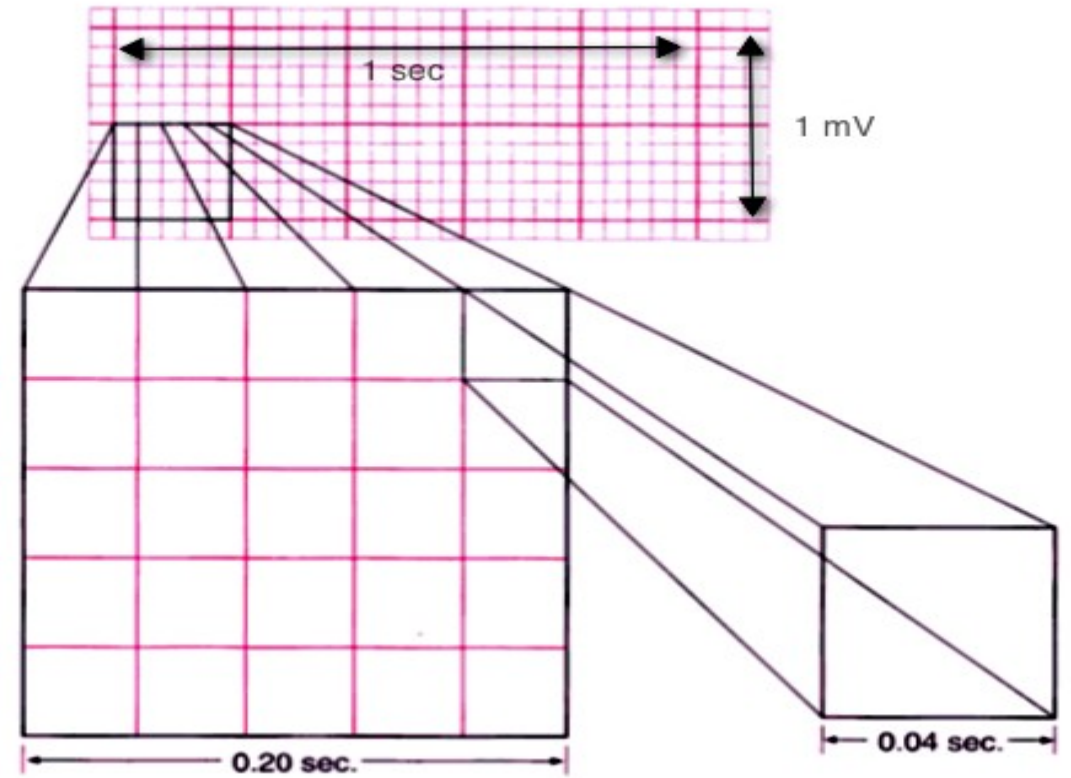
USES OF ECG

Electrocardiogram is useful in determining and diagnosing the following:

- 1. Heart rate**
- 2. Heart rhythm**
- 3. Abnormal electrical conduction**
- 4. Poor blood flow to heart muscle (ischemia)**
- 5. Heart attack**
- 6. Coronary artery disease**
- 7. Hypertrophy of heart chambers**

ELECTROCARDIOGRAPHIC GRID

- The paper that is used for recording ECG is called ECG paper.
- ECG machine amplifies the electrical signals produced from the heart and records these signals on a moving ECG paper.
- Electrocardiographic grid refers to the markings (lines) on ECG paper.
- ECG paper has horizontal and vertical lines at regular intervals of 1 mm.
- Every 5th line (5 mm) is thickened.



DURATION

- Time duration of different ECG waves is plotted horizontally on X-axis.

- **ON X-AXIS**

1 mm = 0.04 second

5 mm = 0.20 second

AMPLITUDE

- Amplitude of ECG waves is plotted vertically on Y-axis.

- **ON Y-AXIS**

1 mm = 0.1 mV

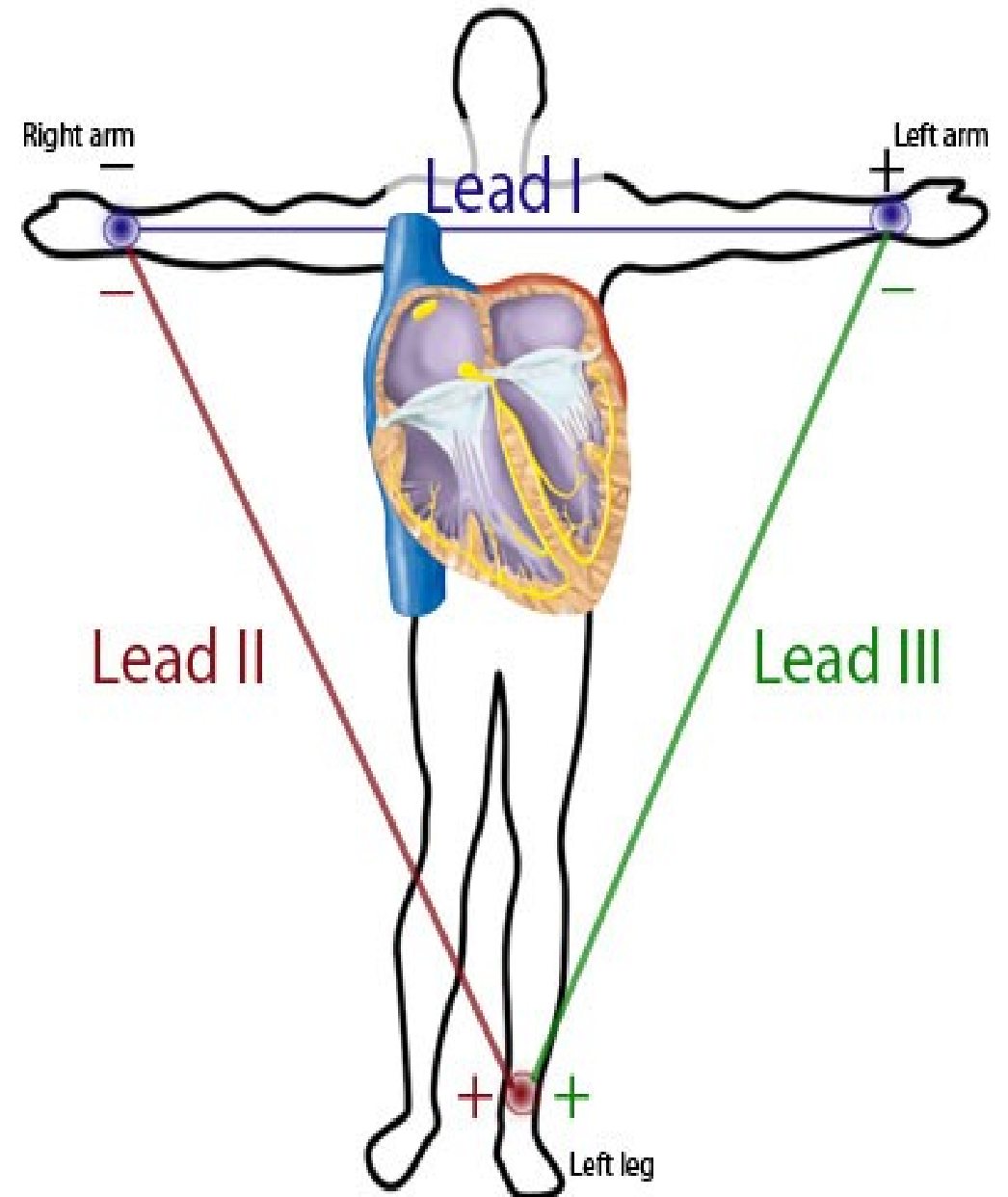
5 mm = 0.5 mV

SPEED OF THE PAPER

- Movement of paper through the machine can be adjusted by two speeds, 25 mm/second and 50 mm/ second.
- Usually, speed of the paper during recording is fixed at 25 mm/second.
- If heart rate is very high, speed of the paper is changed to 50 mm/second.

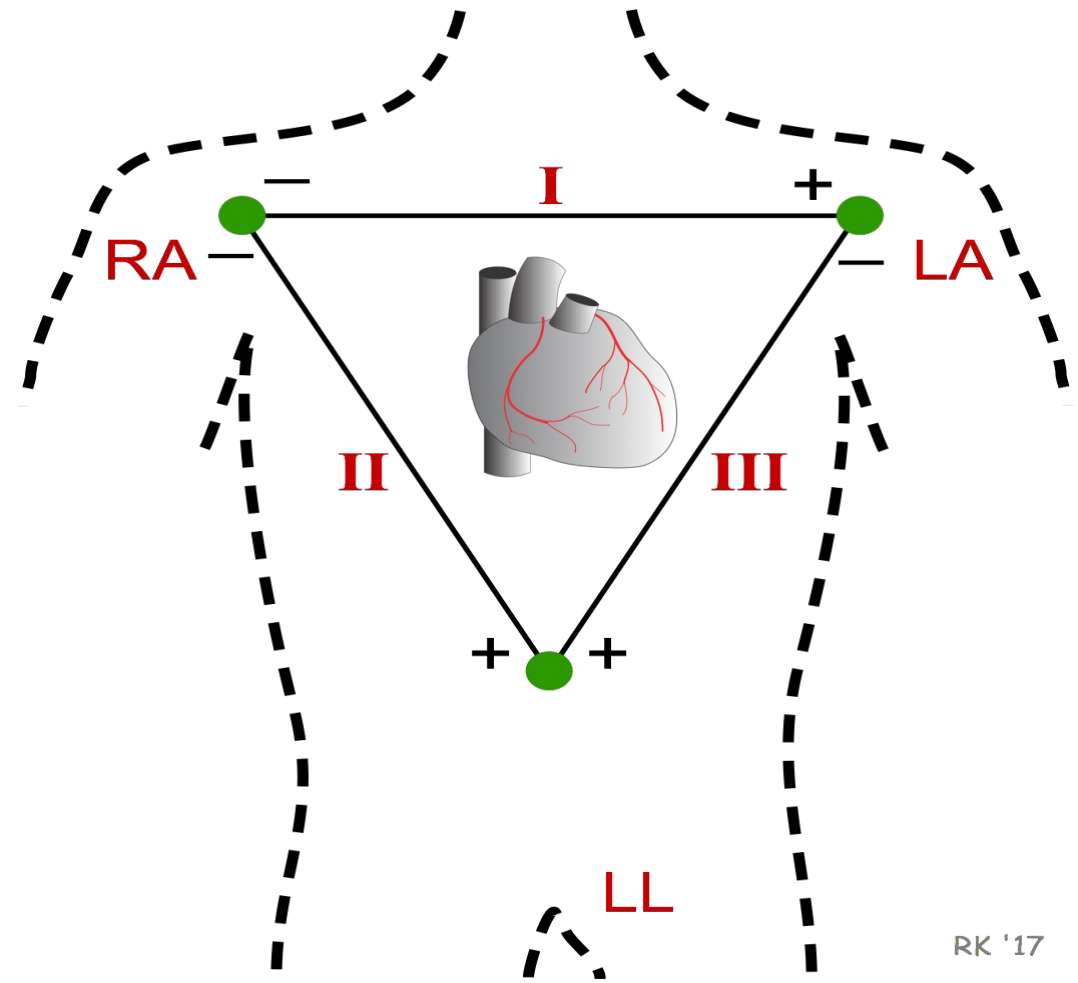
ECG LEADS

- ECG is recorded by placing series of electrodes on the surface of the body.
- These electrodes are called ECG leads and are connected to the ECG machine.
- Electrodes are fixed on the limbs.
- Usually, right arm, left arm and left leg are chosen.
- Heart is said to be in the center of an **imaginary equilateral triangle** drawn by connecting the roots of these three limbs.
- This triangle is called Einthoven triangle.



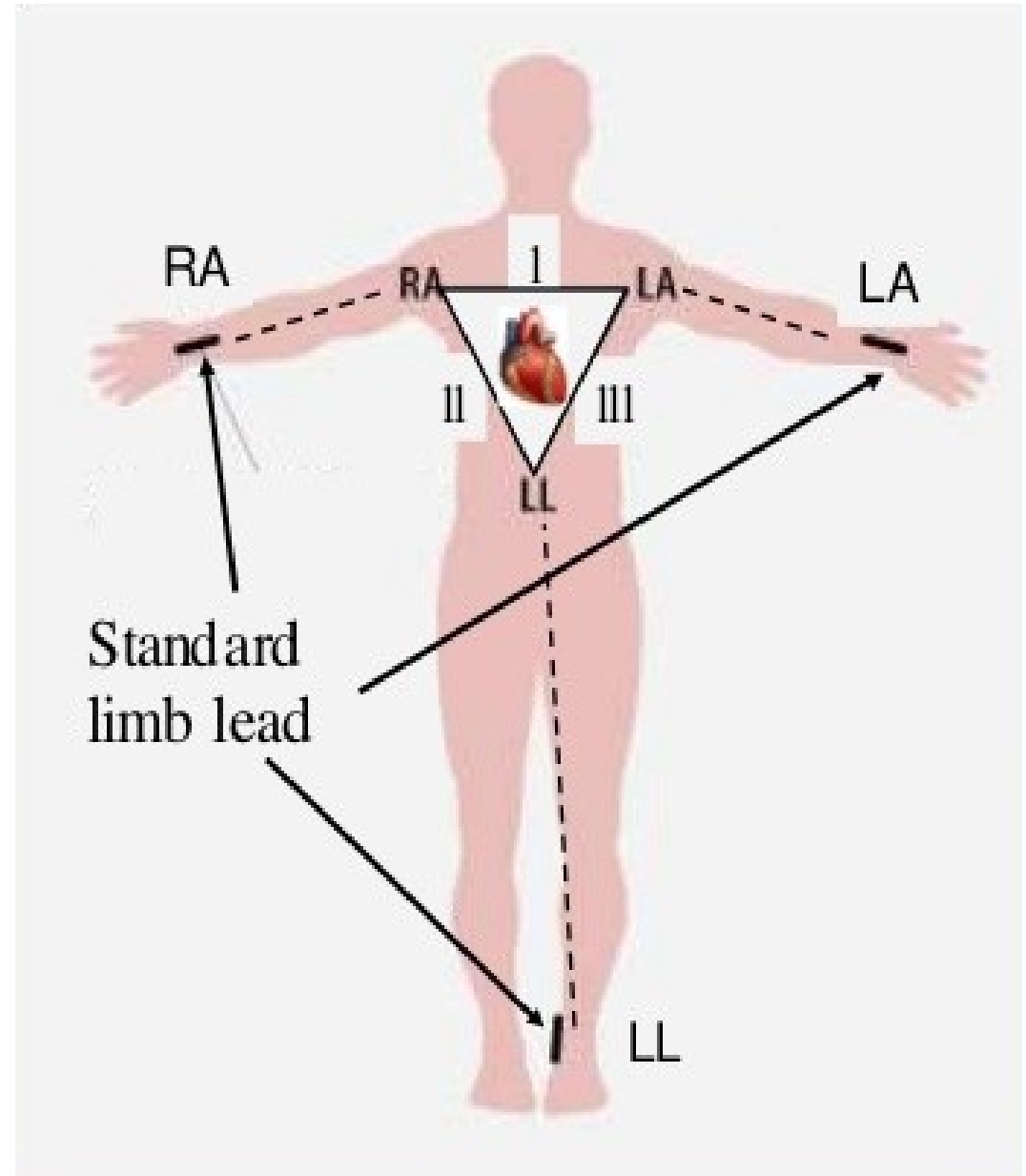
EINTHOVEN TRIANGLE AND EINTHOVEN LAW

- Einthoven triangle is defined as an equilateral triangle that is used as a model of standard limb leads used to record electrocardiogram.
- Heart is presumed to lie in the center of Einthoven triangle.
- Electrical potential generated from the heart appears simultaneously on the roots of the three limbs, namely the left arm, right arm and the left leg.
- ECG is recorded in 12 leads, which are generally classified into two categories.
 - I. Bipolar leads**
 - II. Unipolar leads**



BIPOLAR LIMB LEADS

- Bipolar limb leads are otherwise known as **standard limb leads**.
- Two limbs are connected to obtain these leads and both the electrodes are **active recording electrodes**, i.e. one electrode is positive and the other one is negative.
- Standard limb leads are of three types:
 - a. **LIMB LEAD I**
 - b. **LIMB LEAD II**
 - c. **LIMB LEAD III**



LEAD I

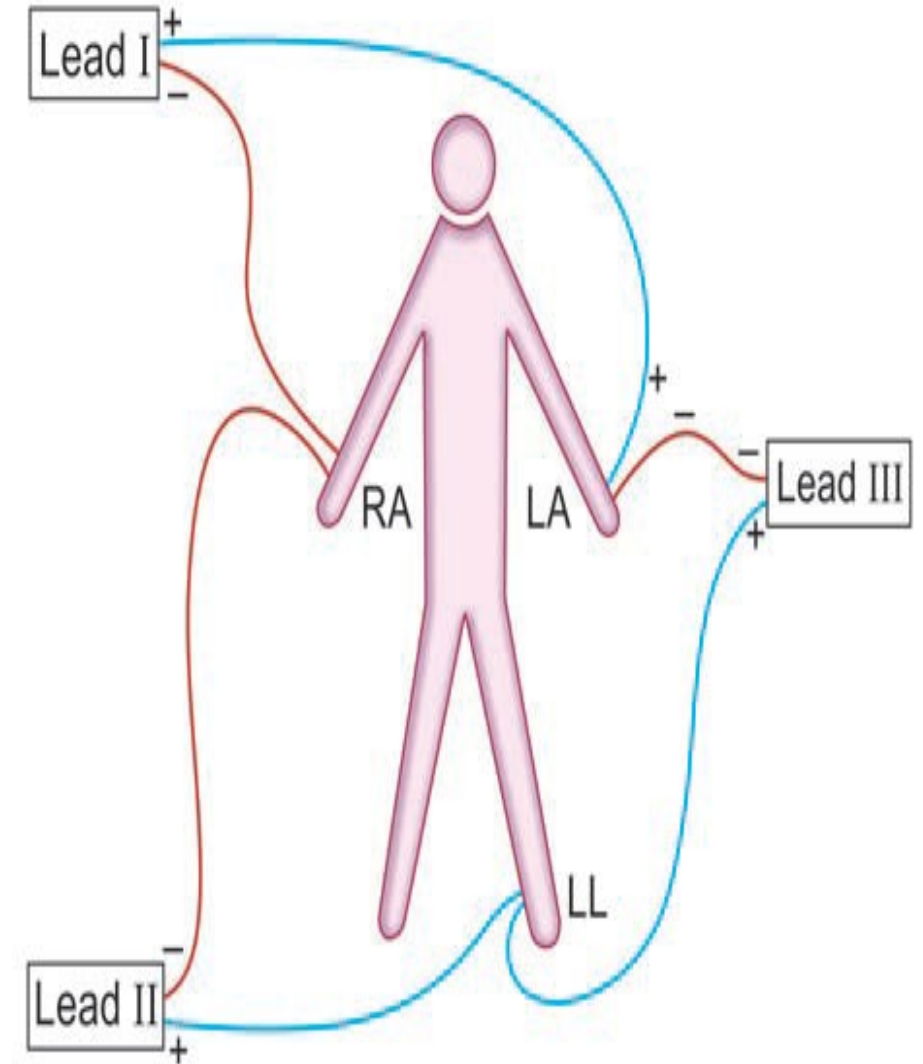
- Lead I is obtained by connecting right arm and left arm.
- Right arm is connected to the negative terminal of the instrument and the left arm is connected to the positive terminal.

LEAD II

- Lead II is obtained by connecting right arm and left leg.
- Right arm is connected to the negative terminal of the instrument and the left leg is connected to the positive terminal.

LEAD III

- Lead III is obtained by connecting left arm and left leg.
- Left arm is connected to the negative terminal of the instrument and the left leg is connected to the positive terminal.



UNIPOLAR LEADS

- Here, one electrode is **active electrode** and the other one is an **indifferent electrode**.
- Active electrode is positive and the indifferent electrode is serving as a **composite negative electrode**.
- Unipolar leads are of two types:
 1. Unipolar limb leads
 2. Unipolar chest leads

1. UNIPOLAR LIMB LEADS

- Unipolar limb leads are also called **augmented limb leads** or **augmented voltage leads**. Active electrode is connected to one of the limbs.
- Indifferent electrode is obtained by connecting the other two limbs through a resistance.
- Unipolar limb leads are of three types:
 - i. aVR lead
 - ii. aVL lead
 - iii. aVF lead

i. aVR LEAD

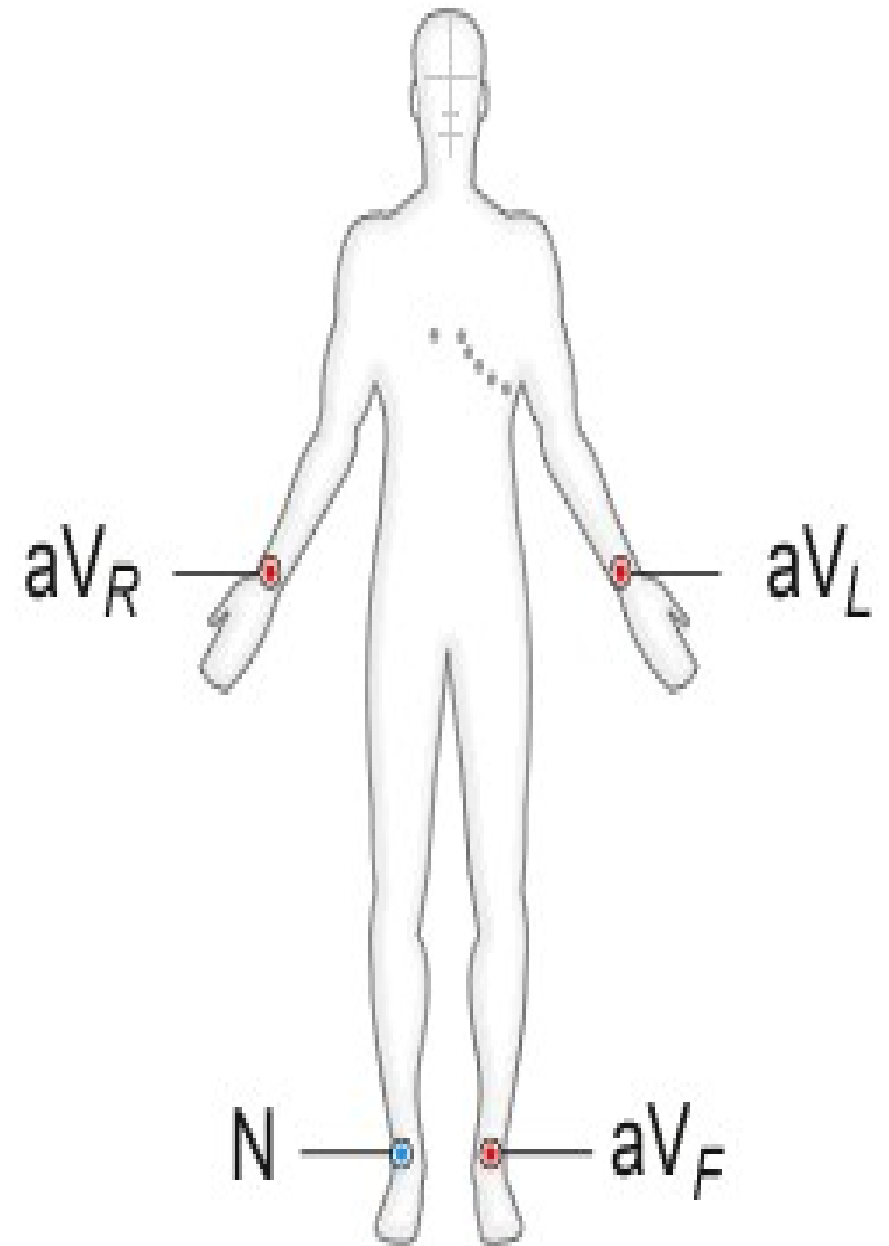
- Active electrode is from right arm.
- Indifferent electrode is obtained by connecting left arm and left leg.

ii. aVL LEAD

- Active electrode is from left arm.
- Indifferent electrode is obtained by connecting right arm and left leg.

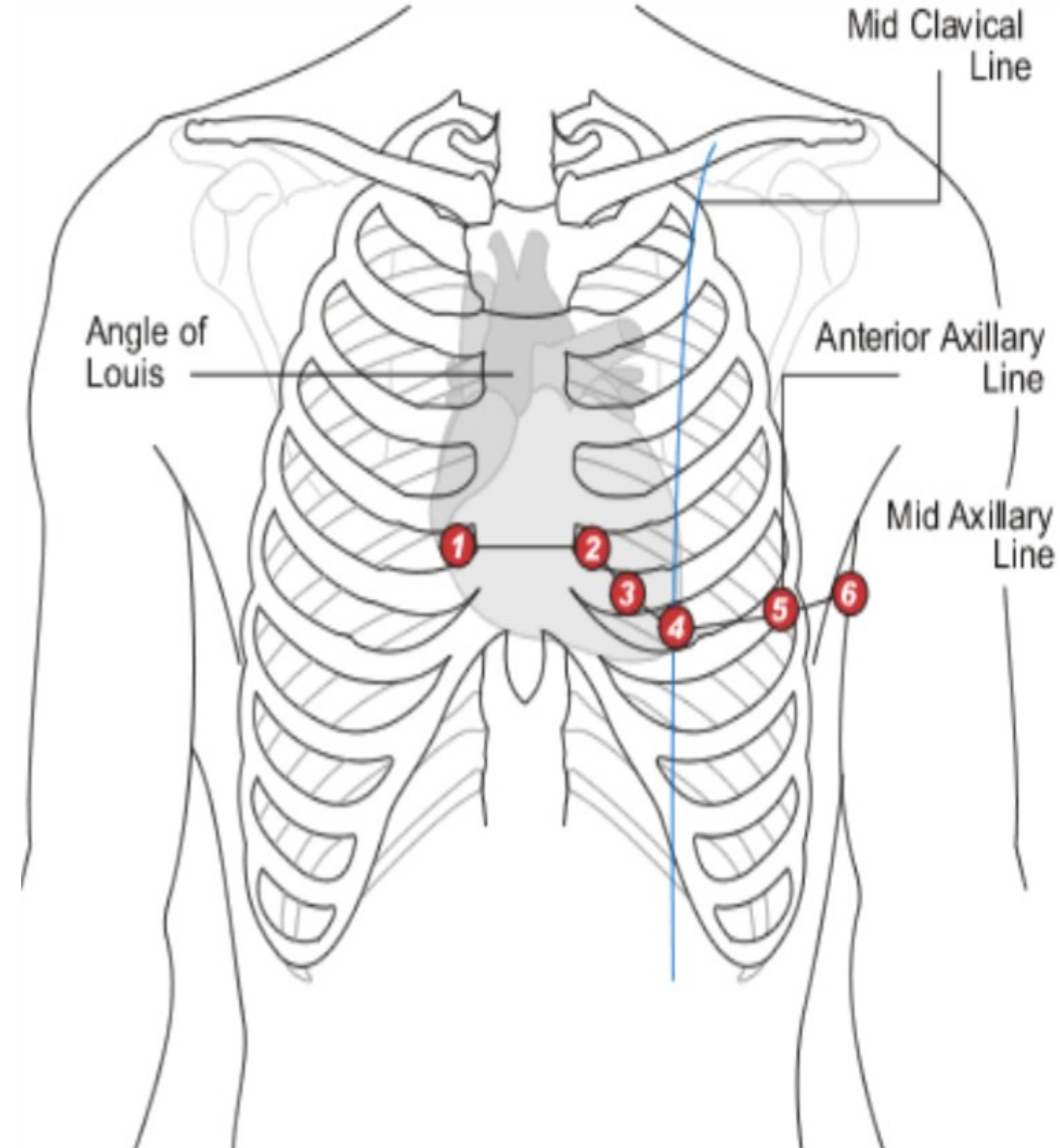
iii. aVF LEAD

- Active electrode is from left leg (foot).
- Indifferent electrode is obtained by connecting the two upper limbs.



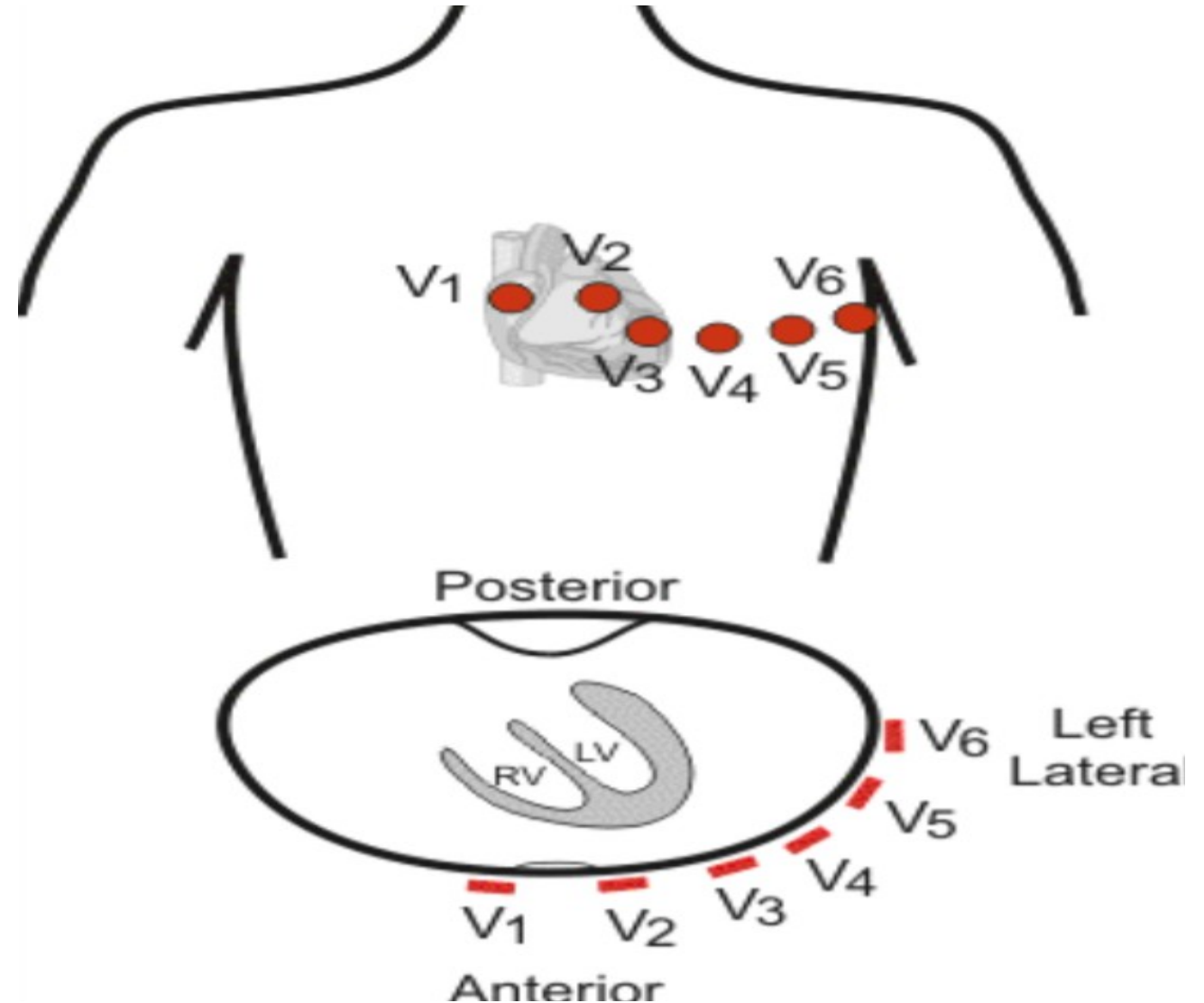
2. UNIPOLAR CHEST LEADS

- Chest leads are also called '**V**' leads or **precordial chest leads**.
- Indifferent electrode is obtained by connecting the three limbs, viz. left arm, left leg and right arm, through a **resistance** of 5000 ohms.
- Active electrode is placed on six points over the chest.
- This electrode is known as the chest electrode and the six points over the chest are called V1, V2, V3, V4, V5 and V6.
- V indicates vector, which shows the direction of current flow.



- **POSITION OF CHEST LEADS:**

- V1** : Over 4th intercostal space near right sternal margin
- V2** : Over 4th intercostal space near left sternal margin
- V3** : In between V2 and V4
- V4** : Over left 5th intercostal space on the mid clavicular line
- V5** : Over left 5th intercostal space on the anterior axillary line
- V6** : Over left 5th intercostal space on the mid axillary line.

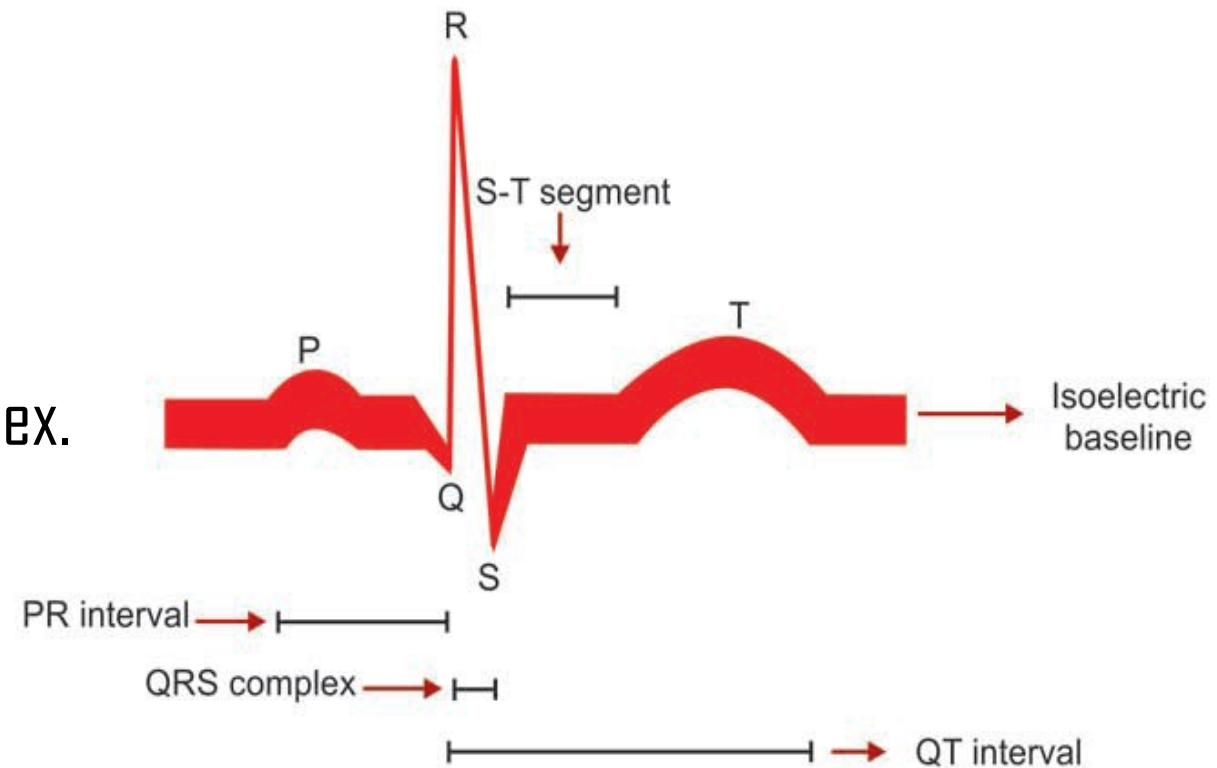


WAVES OF NORMAL ECG

- Normal ECG consists of waves, intervals and segments.
- Waves of ECG recorded by limb lead II are considered as the typical waves.
- Normal electrocardiogram has the following waves, namely P, Q, R, S and T.

MAJOR COMPLEXES IN ECG

1. 'P' wave, the atrial complex.
2. 'QRS' complex, the initial ventricular complex.
3. 'T' wave, the final ventricular complex.
4. 'QRST', the ventricular complex.



'P' WAVE

- 'P' wave is a positive wave and the first wave in ECG.
- It is also called **atrial complex**.

CAUSE

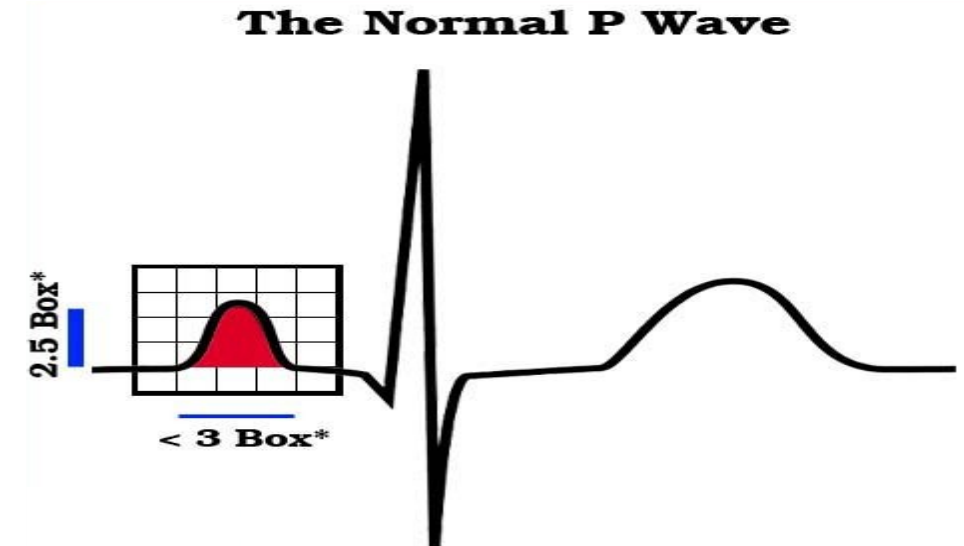
- 'P' wave is produced due to the **depolarization** of **atrial musculature**.
- **Atrial repolarization** is not recorded as a separate wave in ECG because it merges with ventricular repolarization (QRS complex).

DURATION

- Normal duration of 'P' wave is 0.1 second.

AMPLITUDE

- Normal amplitude of 'P' wave is 0.1 to 0.12 mV.



MORPHOLOGY

- 'P' wave is normally positive (upright) in leads I, II, aVF, V4, V5 and V6.
- It is normally negative (inverted) in aVR.
- It is variable in the remaining leads, i.e. it may be positive, negative, biphasic or flat.

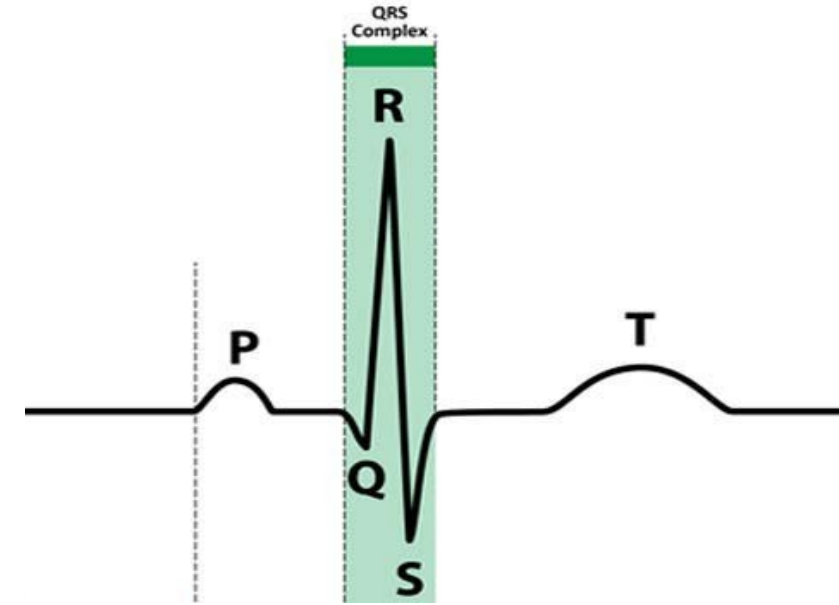
CLINICAL SIGNIFICANCE

- Variation in the duration, amplitude and morphology of 'P' wave helps in the diagnosis of several cardiac problems such as:
 1. **RIGHT ATRIAL HYPERTROPHY:** 'P' wave is tall (more than 2.5 mm) in lead II. It is usually pointed.
 2. **LEFT ATRIAL DILATATION OR HYPERTROPHY:** It is tall and broad based or M shaped.
 3. **ATRIAL EXTRASYSTOLE:** Small and shapeless 'P' wave, followed by a small compensatory pause.
 4. **HYPERKALEMIA:** 'P' wave is absent or small.
 5. **ATRIAL FIBRILLATION:** 'P' wave is absent.

The QRS Complex

'QRS' COMPLEX

- 'QRS' complex is also called the **initial ventricular complex**.
- 'Q' wave is a small negative wave.
- It is continued as the tall 'R' wave, which is a positive wave.
- 'R' wave is followed by a small negative wave, the 'S' wave.



CAUSE

- 'QRS' complex is due to **depolarization of ventricular musculature**.
- 'Q' wave is due to the depolarization of basal portion of interventricular septum.
- 'R' wave is due to the depolarization of apical portion of interventricular septum and apical portion of ventricular muscle.
- 'S' wave is due to the depolarization of basal portion of ventricular muscle near the atrioventricular ring.

DURATION

- Normal duration of 'QRS' complex is between 0.08 and 0.10 second.

AMPLITUDE

- Amplitude of 'Q' wave = 0.1 to 0.2 mV.
- Amplitude of 'R' wave = 1 mV.
- Amplitude of 'S' wave = 0.4 mV.

MORPHOLOGY

- 'Q' wave is normally small with amplitude of 4 mm or less.
- It is less than 25% of amplitude of 'R' wave in leads I, II, aVL, V5 and V6. In the remaining leads, its amplitude is < 0.2 mm.
- From chest leads V1 to V6, 'R' wave becomes gradually larger. It is smaller in V6 than V5.
- 'S' wave is large in V1 and larger in V2. It gradually becomes smaller from V3 to V6.

CLINICAL SIGNIFICANCE

- Variation in the duration, amplitude and morphology of 'QRS' complex helps in the diagnosis of several cardiac problems such as:
 1. **BUNDLE BRANCH BLOCK:** QRS is prolonged or deformed.
 2. **HYPERKALEMIA:** QRS is prolonged.

'T' WAVE

- 'T' wave is the **final ventricular complex** and is a positive wave.

CAUSE

- 'T' wave is due to the **repolarization of ventricular musculature.**

DURATION

- Normal duration of 'T' wave is 0.2 second.

AMPLITUDE

- Normal amplitude of 'T' wave is 0.3 mV.

MORPHOLOGY

- 'T' wave is normally positive in leads I, II and V5 and V6.
- It is normally inverted in lead aVR. It is variable in the other leads, i.e. it is positive, negative or flat.

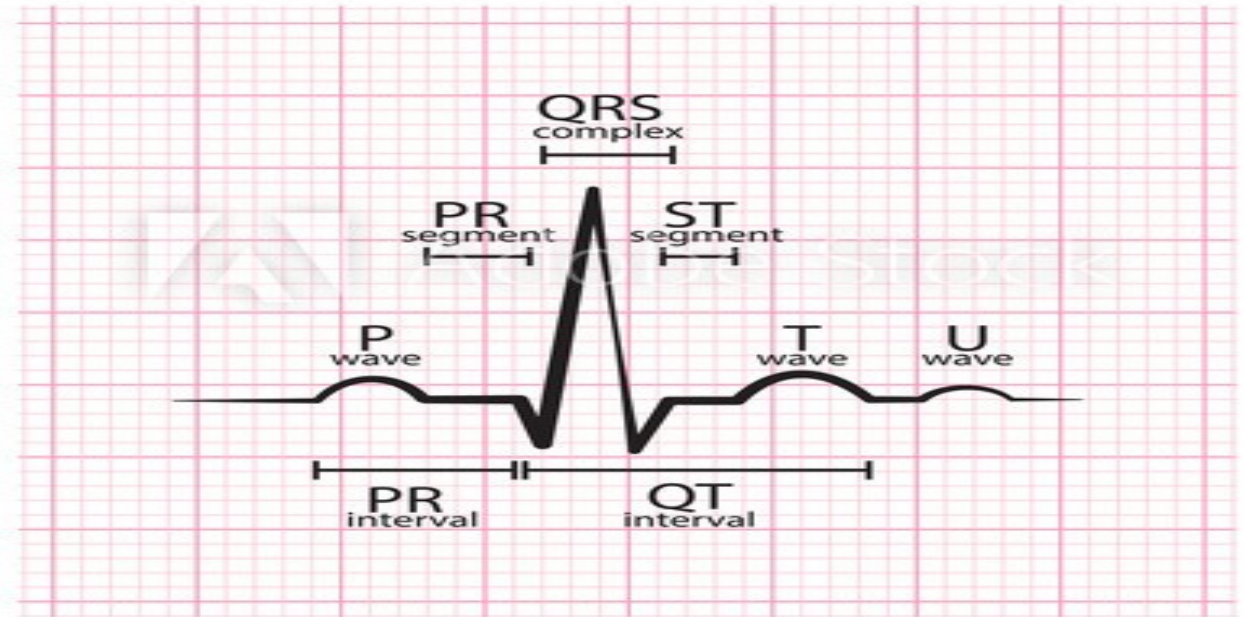
CLINICAL SIGNIFICANCE

- Variation in duration, amplitude and morphology of 'T' wave helps in the diagnosis of several cardiac problems such as:
 1. **ACUTE MYOCARDIAL ISCHEMIA:** Hyperacute 'T' wave develops. Hyperacute 'T' wave refers to a tall and broad-based 'T' wave, with slight asymmetry.
 2. **OLD AGE, HYPERVENTILATION, ANXIETY, MYOCARDIAL INFARCTION, LEFT VENTRICULAR HYPERTROPHY AND PERICARDITIS:** 'T' wave is small, flat or inverted.
 3. **HYPOKALEMIA:** 'T' wave is small, flat or inverted.
 4. **HYPERKALEMIA:** 'T' wave is tall and tented.

'U' WAVE

- 'U' wave is not always seen. It is also an insignificant wave in ECG.
- It is supposed to be due to **repolarization** of **papillary muscle**.

NORMAL ECG



CLINICAL SIGNIFICANCE

- Appearance of 'U' wave in ECG indicates some clinical conditions such as:
 1. **HYPERCALCEMIA, THYROTOXICOSIS AND HYPOKALEMIA:** 'U' wave appears. It is very prominent in hypokalemia.
 2. **MYOCARDIAL ISCHEMIA:** Inverted 'U' wave appears.

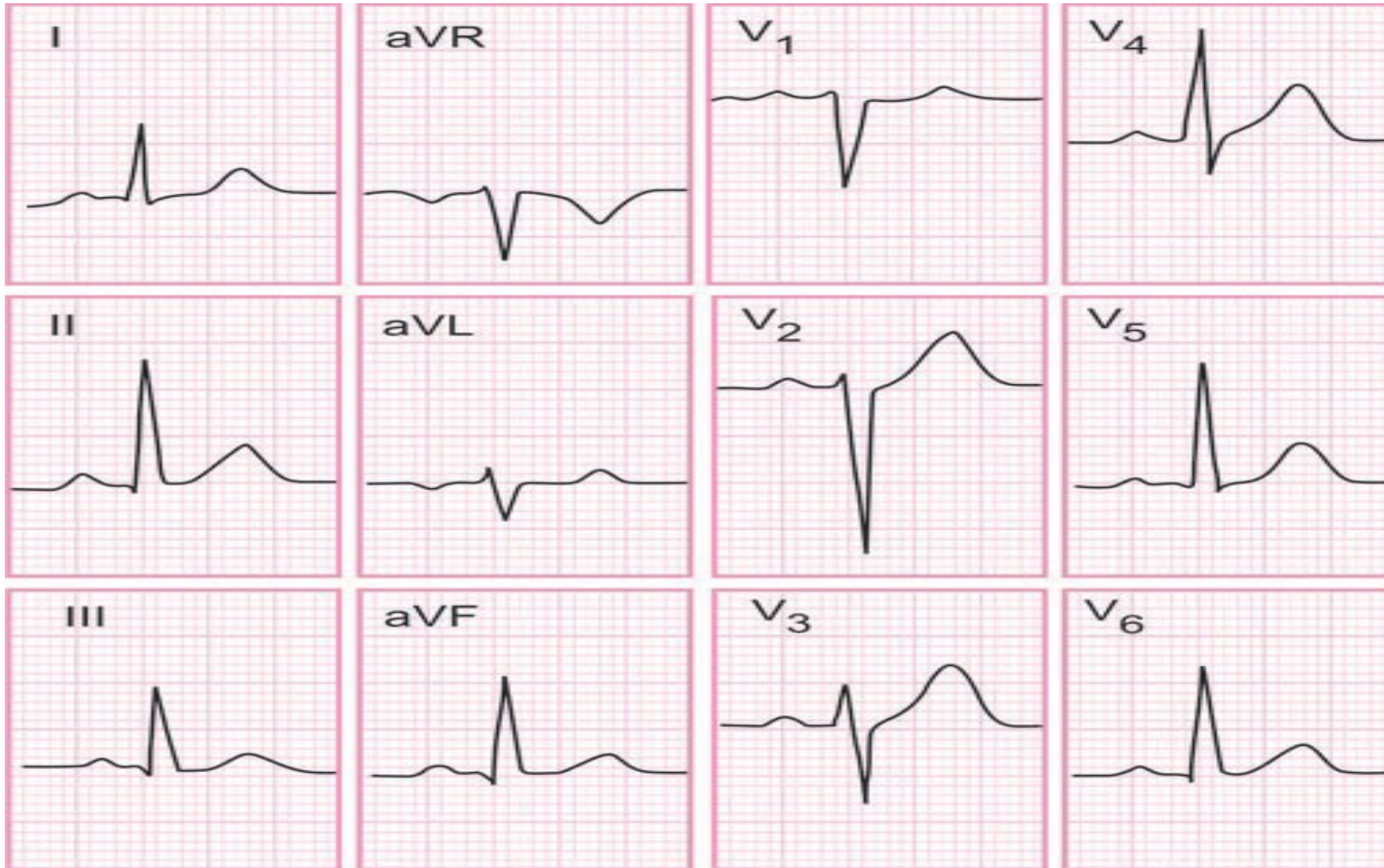
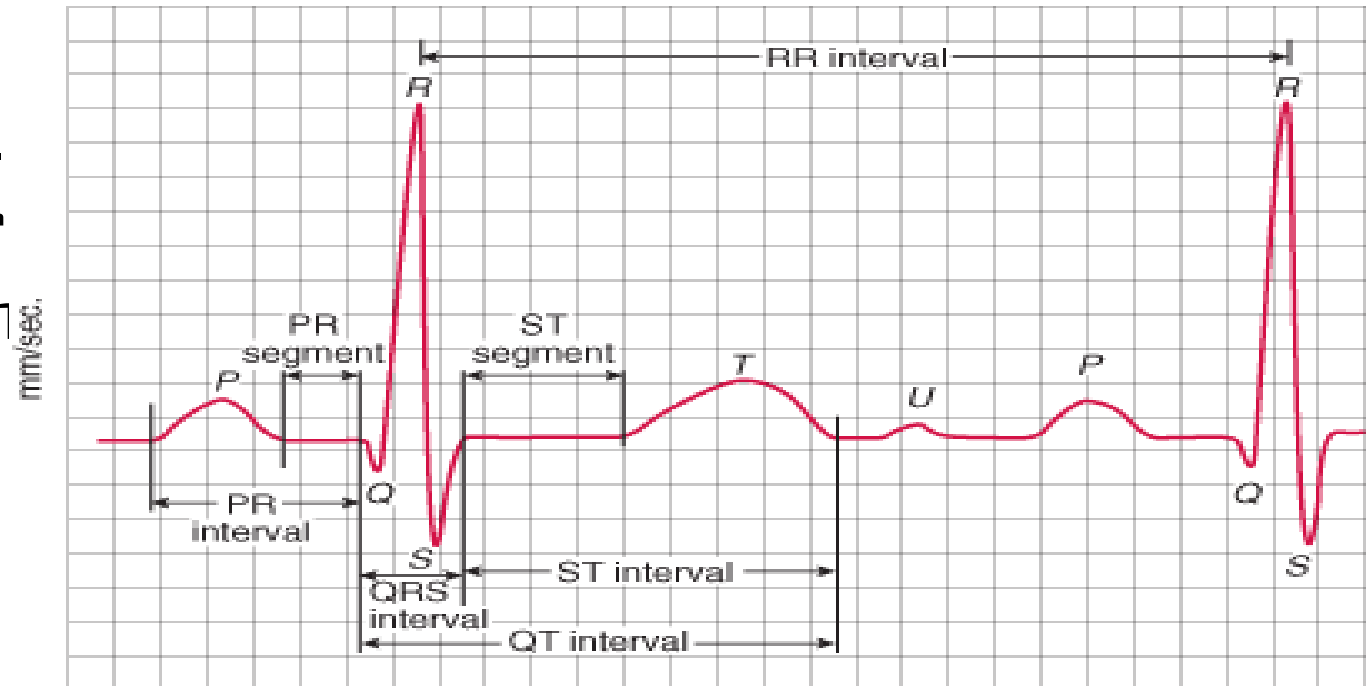


FIGURE : ALL 12-LEADS NORMAL ECG

INTERVALS AND SEGMENTS OF ECG

'P-R' INTERVAL

- 'P-R' interval is the interval between the onset of 'P' wave and onset of 'Q' wave.
- 'P-R' interval signifies the atrial depolarization and conduction of impulses through AV node.
- It shows the duration of conduction of the impulses from the SA node to ventricles through atrial muscle and AV node.
- 'P' wave represents the atrial depolarization.
- Short **isoelectric** (zero voltage) period after the end of 'P' wave represents the time taken for the passage of depolarization within AV node.



mm/mV 1 square = 0.04 sec/0.1mV

DURATION

- Normal duration of 'P-R interval' is 0.18 second and varies between 0.12 and 0.2 second.
- If it is more than 0.2 second, it signifies the delay in the conduction of impulse from SA node to the ventricles. Usually, the delay occurs in the AV node.
- It is called the **AV nodal delay**.

CLINICAL SIGNIFICANCE

- Variation in the duration of 'P-R' intervals helps in the diagnosis of several cardiac problems such as:
 1. It is prolonged in bradycardia and first degree heart Block.
 2. It is shortened in tachycardia, Wolf-Parkinson- White syndrome, Lown-Ganong-Levine syndrome, Duchenne muscular dystrophy and type II glycogen storage disease.

'Q-T' INTERVAL

- 'Q-T' interval is the interval between the onset of 'Q' wave and the end of 'T' wave.
- 'Q-T' interval indicates the ventricular depolarization and ventricular repolarization,

i.e. it signifies the electrical activity in ventricles.

DURATION

- Normal duration of Q-T interval is between 0.4 and 0.42 second.

CLINICAL SIGNIFICANCE

1. 'Q-T' interval is prolonged in long 'Q-T' syndrome, myocardial infarction, myocarditis, hypocalcemia and hypothyroidism.
2. 'Q-T' interval is shortened in short 'Q-T' syndrome and hypercalcemia.

'S-T' SEGMENT

- 'S-T' segment is the time interval between the end of
- 'S' wave and the onset of 'T' wave. It is an isoelectric period.

J POINT

- The point where 'S-T' segment starts is called 'J' point.
- It is the junction between the QRS complex and 'S-T' segment.

DURATION OF 'S-T' SEGMENT

- Normal duration of 'S-T' segment is 0.08 second.

CLINICAL SIGNIFICANCE

- Variation in the duration of 'S-T' segment and its deviation from isoelectric base indicates the pathological conditions such as:
 1. Elevation of 'S-T' segment occurs in anterior or inferior myocardial infarction, left bundle branch block and acute pericarditis. In athletes, 'S-T' segment is usually elevated.
 2. Depression of 'S-T' segment occurs in acute myocardial ischemia, posterior myocardial infarction, ventricular hypertrophy and hypokalemia.
 3. 'S-T' segment is prolonged in hypocalcemia.
 4. 'S-T' segment is shortened in hypercalcemia.

'R-R' INTERVAL

- 'R-R' interval is the time interval between two consecutive 'R' waves.

SIGNIFICANCE

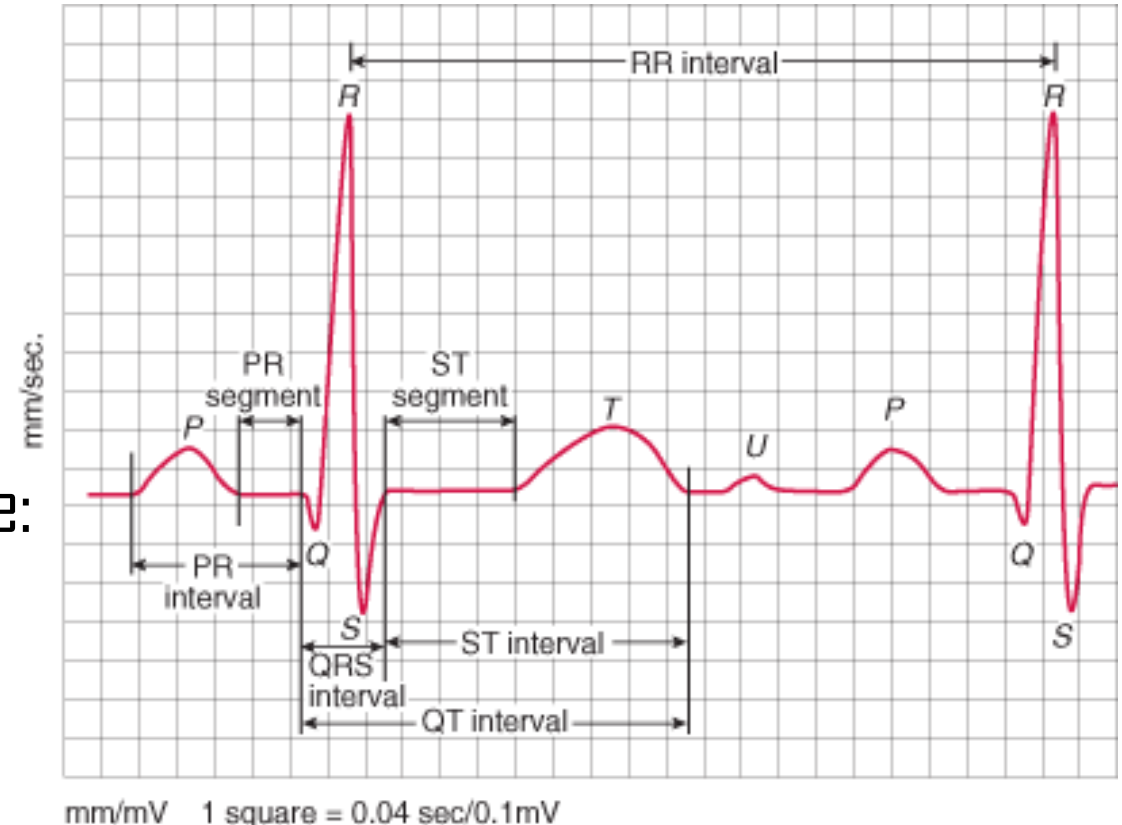
- 'R-R' interval signifies the duration of one cardiac cycle.

DURATION

- Normal duration of 'R-R' interval is 0.8 second.

SIGNIFICANCE OF MEASURING 'R-R' INTERVAL

- Measurement of 'R-R' interval helps to calculate:
 1. Heart rate
 2. Heart rate variability



1. HEART RATE

- Heart rate is calculated by measuring the number of 'R' waves per unit time.

2. HEART RATE VARIABILITY

- Heart rate variability (HRV) refers to the beat-to-beat variations.
- Under resting conditions, the ECG of healthy individuals exhibits some periodic variation in 'R-R' intervals.
- This rhythmic phenomenon is known as **respiratory sinus arrhythmia** (RSA), since it fluctuates with the phases of respiration.

SIGNIFICANCE OF HEART RATE VARIABILITY

- HRV decreases in many clinical conditions like:
 1. Cardiovascular dysfunctions such as hypertension.
 2. Diabetes mellitus
 3. Psychiatric problems such as panic and anxiety.

THANK YOU