


Diaper Dermatitis

AHIPUTANA




Dr. Dhananjay Dilip Deshmukh (M.D.)
9765745023

INTRODUCTION

- ▶ One among kshudra roga.
 - ▶ Mentioned by sushruta in Kshudraroga nidana, Nidanasthana 13th chapter.
 - ▶ Adhithana is Guda.
 - ▶ Dosa is Kapha–Raktha.
 - ▶ Age group: Infant
- 

SYNONYMS

- ▶ Matrka dosa
 - ▶ Prstaru
 - ▶ Gudakuttakam
 - ▶ Anaamika
- 

Acc. To Su.S. Ni;

शक्रन्मूत्रसमायुक्ते अधोते अपाने शिशोर्भवेत्।

स्विन्नस्यास्त्राप्यमानस्य कण्डू रक्तक्फोद्भवा॥


कण्डूयनात्ततः क्षिप्रम् स्फोटाः स्रावश्च जायते।

एकीभूतम् व्रणघोरम् तम् विद्वादहिपूतनम्॥

(su.ni.13/57)

NIDANA


UNHYGIENIC CONDITIONS :

- ▶ Absence of proper cleaning after defecation & urination.
 - ▶ Negligence of bath after oversweating.
- 

SAMPRAPTHI

Nidana → Kapha– Raktha Kopa → Kandu →
Kshipra Sphota with Srava → Join to form
Vrana.

CLINICAL FEATURES


- ▶ Kandu
 - ▶ Sphota
 - ▶ Srava
 - ▶ Vrana
- 

CHIKITSA (Acc. to Su.S.Chi)


धात्र्याः स्तन्यम् शोधयित्वा बाले साध्या अहिपूतना।
पटोलपत्रत्रिफलारसान्जनविपाचितम्॥
पीतम् घृतम् नाशयति क्रच्छामाप्यहिपूतनाम्।
त्रिफलाकोलखदिरकषायम् व्रणरोपणम्॥
कासीसरोचनातुत्थहरितालरसान्जनैः।
लेपो अम्लपिष्टो बदरीत्वग्वा सैन्धवसम्युता॥
कपालतुत्थजम् चूर्णम् चूर्णकाले प्रयोजयेत्।

(su.chi.20/57)

TREATMENT


- ▶ Dhathri stanya shodana by pittahara and sleshmahara measures.
 - ▶ Internal administeration of ghrtha prepared from Patola pathra, Triphala & Rasanjana.
 - ▶ Vrana ropana with Triphala, Kola & Khadira kvatha.
- 

CONTD.....

- ▶ Lepa with Kasisa, Gorochana, Thutha, Haritala & Rasanjana. or
 - ▶ Lepa with Badari tvak added with saindhava & macerated with any sour juice.
 - ▶ Avachurnana with Kapala churna & Thutha churna.
- 


NAPKIN DERMATITIS

Also be called as :


- ▶ Diaper Rash
 - ▶ Nappy Rash
 - ▶ Diaper Dermatitis
- 

DEFINITION


It is an inflammatory disorder characterized by the development of erythema, papules & sometimes vesiculation with scaling affecting the napkin or diaper area of usually infants.



ETIOLOGY

- ▶ Very common
 - ▶ Some babies get sore bottom very easily, others very rarely, but they all grow out of it when they stop wearing nappies.
- 


FACTORS ASSOCIATED WITH ETIOLOGY:

- Irritant Contact Dermatitis: Urine & faeces will cause a rash on any skin left in contact for long enough.
Ammonia is formed and burns the skin.
 - ▶ Infection with bacteria & candida yeasts.
- 

CONTD.....


- ▶ Other skin disorders like Psoriasis and Atopic Dermatitis can affect the Napkin area.

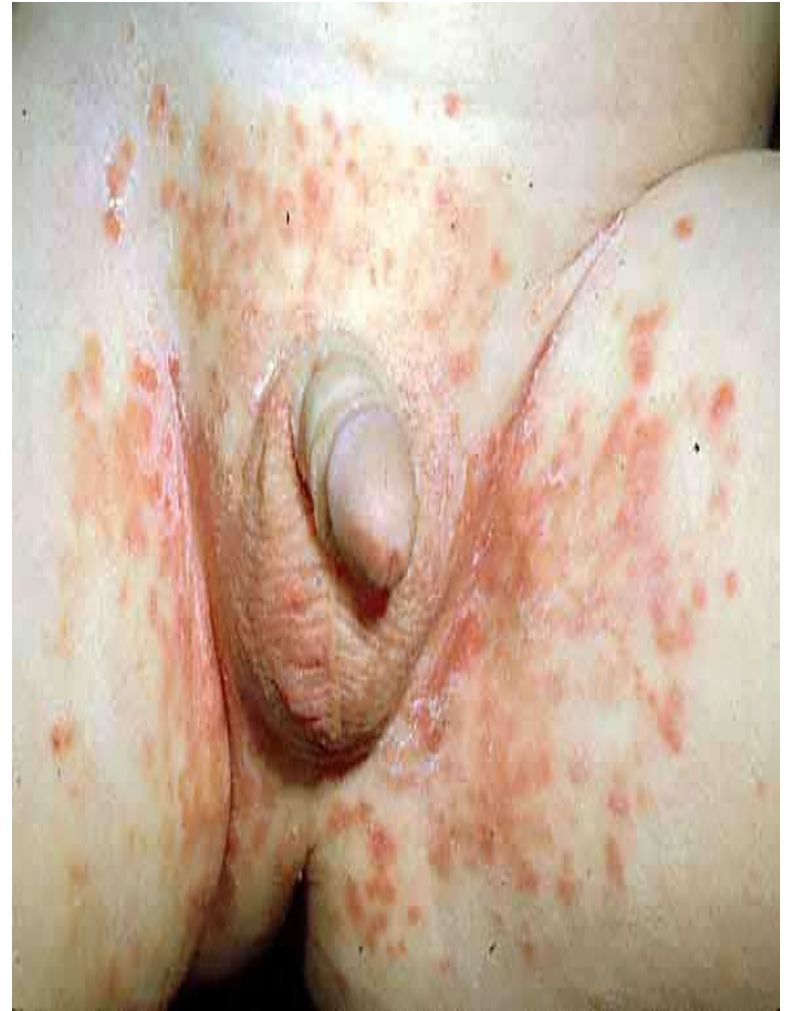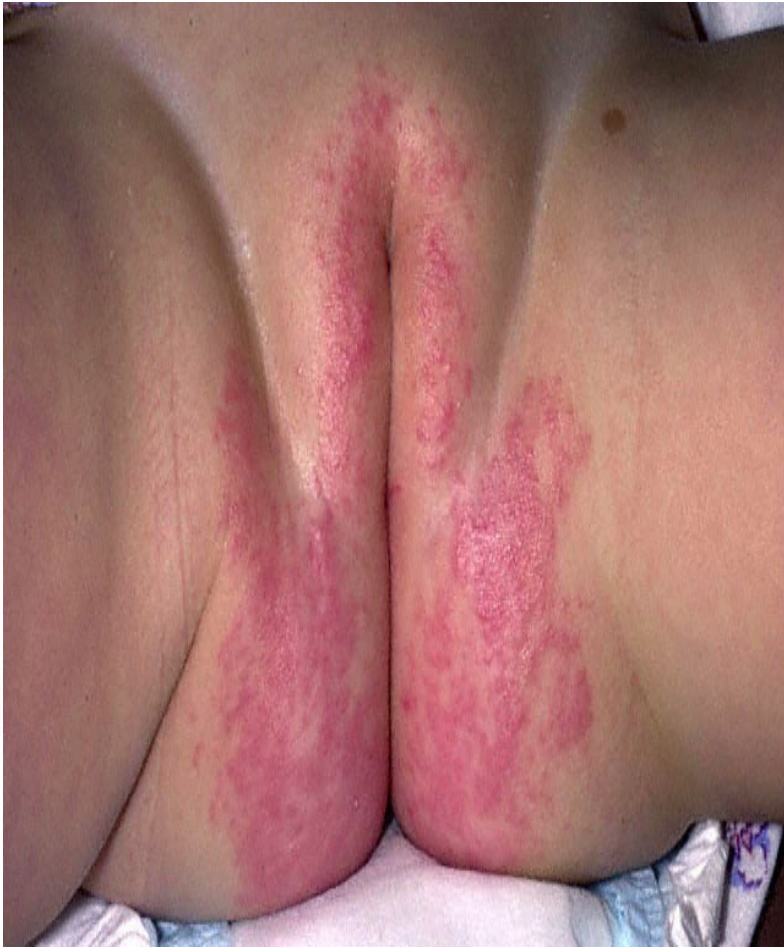CLINICAL EVALUATION

- ❑ Disease is characterised by development of erythema in its early stages.
 - ❑ Followed by formation of vesicles that rupture to ooze out serous discharge.
 - ❑ Lesions resolve with scaling.
- 


CONTD.....

Areas affected are: Convexities such as Prominences of ;

- ❖ Pubis
 - ❖ Thighs &
 - ❖ Buttocks
- 



TREATMENT


- ✓ Frequent diaper changes & short periods without diapers are important adjunctive treatment.
 - ✓ Area should be washed following a bowel movement.
 - ✓ Washing should be done with warm water only.
- 

CONTD.....


- ✓ Air drying is useful.
- ✓ Long standing diaper rash should be treated with topical antifungal therapy such as nystatin cream, powder or ointment; clotrimazole 1% cream; miconazole 2% ointment etc.

TIPS TO PARENTS


INCLUDE:

- Use disposable nappies.
 - If cloth nappies are used, make sure the nappies are rinsed and dried well after washing.
- 

CONTD.....

- Change the nappies frequently.
 - Do not leave your baby in wet or dirty nappy.
 - Wash the babys bottom at every change.
- 

CONTD.....

- Use warm water to remove all urine & bowel motions.
 - Pat dry frequently.
 - Moisturize dry skin at every nappy change.
- 

THANK YOU

